

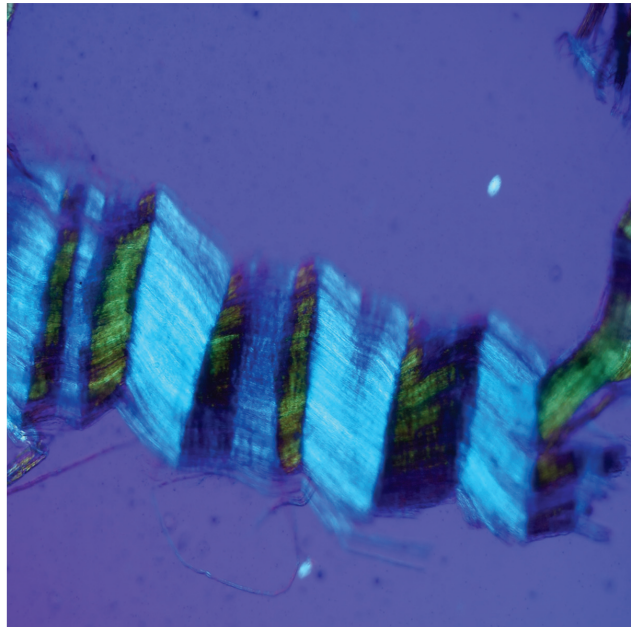


Microscopy TODAY

Volume 29 Number 2 2021 March



First Report of Peripheral Nerves in Bone from *Triceratops horridus* Occipital Condyle

Mark H. Armitage

DSTRI, Inc. 325 East Washington Street #170, Sequim, WA 98382

micromark@juno.com

Abstract: Peripheral nerves in vertebrate systems have been studied for centuries. Nerve anatomy, including the connective tissues that cushion nerves, are well described in the literature. The outer connective tissues, known as the epineurium and perineurium, include a double layer of collagen fibers that form a double helical wrapping that is visible with polarized light microscopy and by other contrast methods. This wrapping is a diagnostic characteristic of nerve tissues. Decades of research into dinosaur bones have produced interesting endocasts of probable brain morphology, but no soft and flexible nerve tissues have been reported from dinosaur remains. In this study we provide evidence of nerve fragments, characterized by a double helical wrapping of collagen fibers, from a *Triceratops* condyle collected at the Hell Creek Formation, MT. Based on comparison with nerves from an avian model we conclude that these are fragments of nerves that once resided *in vivo* in *Triceratops*.

Keywords: dinosaur, nerves, fascicles, epineurium, perineurium

Introduction

Peripheral nerve tissue and its connective elements have been the subject of intense study for over 350 years [1]. Examination of these structures using magnification precedes even Anthony van Leeuwenhoek, who himself illustrated the structure of desiccated bovine optic nerves and later peripheral nerves [2,3].

Peripheral nerves are constructed as fascicles (bundles of nerve fibers), surrounded by multiple layers of insulating connective tissue [4–19]. Figures 1 and 2 show the most easily discernible insulating tissue layers from fixed avian sciatic nerve under low magnification (arrows). Each bundle of nerves contains the axons that transmit electrical signals (Figure 3).

Nerve connective tissue layers are labeled according to their position within the nerve [7,15–19]. The epineurium (Figures 1 and 4) is the outermost layer of the nerve and is described as loose connective tissue that circumscribes and cushions bundles of nerve fascicles (with their internal axons) and the vessels and veins that supply it. Upon dissection the epineurium separates into external and internal layers [15]. The perineurium (Figure 2) surrounds individual bundles of fibers known as fascicles. One fascicle (Figure 5) is the smallest unit of a nerve fiber that can be isolated via dissection. Within a fascicle there might be dozens to hundreds of individual fibers. Each fiber within the fascicle is wrapped in endoneurium, another connective tissue type. Additionally, myelin sheaths often cover the axon proper. Myelin insulates and protects axons at the center of each fiber.

Certain structural characteristics of the epineurium and perineurium elude clarity, but the much noted and remarkable double helix of circumferential wrapping of collagen fibers characteristic of these layers is well established [7,8,10,13–17] (Figure 6). Note the double helix pattern formed by the collagen wrapping of the covering on a nerve harvested from decalcified

avian bone (Figure 7). There is disagreement over whether the epineurium is the site of such crosshatch wrapping [8,13–15] or whether it lies within the perineurium [7,10,11,16,17]. Curiously, some structural studies of nerve connective tissue fail to mention a wrapping pattern at all [9,12,18,19]. Stolinski [15] posits that this weave pattern is restricted to the inner side of the epineurium. This was visible to him when using reflected oblique illumination. However, Glees [7] employed polarized light examination and illustrated the double helix as part of the perineurium (Figure 6).

Bands of Fontana are an optical effect [20] of light reflecting off and being refracted by the axonal fibers deep inside nerve bundles (Figures 3a and 3b). These are arranged in a permanent sinusoidal pleated wave down the long axis of the nerve. Confusion might result from the anisotropic nature of some connective tissues of nerves [7] as well as the microscope illumination methods used [21]. Nevertheless, collagen fibers in the epineurium and/or the perineurium are seen to wrap, in a double helical fashion, at oblique angles around the long axis of the peripheral nerve fiber, forming a characteristic crosshatch pattern (Figure 7). This is a diagnostic feature of the epineurium and perineurium of peripheral nerves that is visible with polarized light and other contrast methods.

In addition to soft tissues, bones are deeply innervated by sympathetic and sensory nerves [22–26]. These nerves, along with a corresponding blood supply, travel within Haversian and Volkmann's canals and often produce dense networks [22–24,26]. The highest density of nerve fibers is known to exist within areas of bone that face the greatest mechanical stress [23], although some reports maintain that much of bone is simply devoid of certain nerves, especially sensory fibers [26,27]. Nevertheless, it would be expected based on current understanding of vertebrate bone anatomy that nerves should reside *in vivo* within bone canals of dinosaur bones as neurovascular bundles traveling with arteries and veins [22–25].

Paleoneurological studies have been conducted on dinosaur remains for decades [28–36]. Natural brain endocasts (as a result of infiltration of sediments), injection-molded endocasts filled with liquid polymers that later harden, and high-resolution X-ray tomography have all provided interesting models of brains for study. However, there have been no reports of the presence of soft and flexible nerves in dinosaur remains. The purpose of this study was to harvest and characterize nerves from *Triceratops* condyle collected at the Hell Creek Formation, MT.

Methods

Chicken legs, commercially available from the market, were dissected and peripheral nerves removed. These were

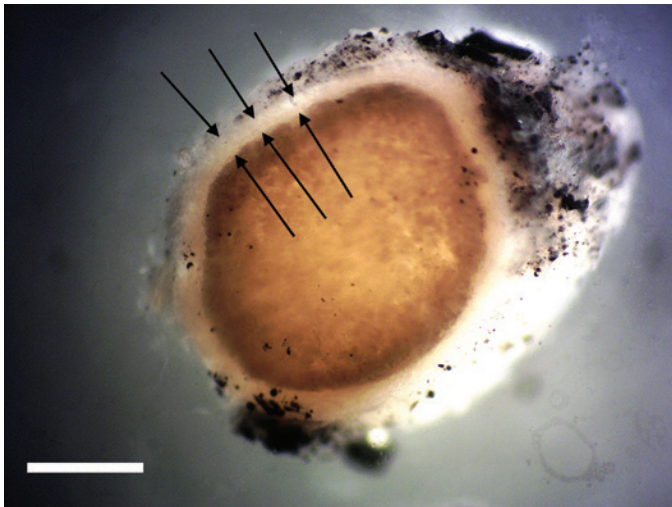


Figure 1: Cross section of avian peripheral nerve showing thick outer layer of epineurium covering (arrows). Darkened nerve fibers stained with OsO_4 fill the lumen of the epineurium. Scale bar = 0.5 mm.

lightly fixed in 2.5% glutaraldehyde/0.2M sodium cacodylate buffer, pH 7.4, for 20 minutes, washed and used for gross dissection (Figures 1–4). Leg bones were also removed, denuded of tissue, and similarly fixed. After fixation, bones were cleaved longitudinally with a blade. Once rinsed in distilled water, long pieces of chicken bones were decalcified in 14% sodium EDTA at room temperature in glass culture dishes with agitation. Narrowly focused oblique illumination was used to identify and capture individual bone nerve fascicles (Figure 5) and bone nerves (Figure 7) liberated via decalcification. Nerves glowed brightly against a black background in solution, which allowed capture of fibers at their ends with fine needle forceps. These nerves were washed in distilled water and post-fixed in 2% osmium tetroxide for 15 minutes. After washing again, nerves were processed through a dehydration series using

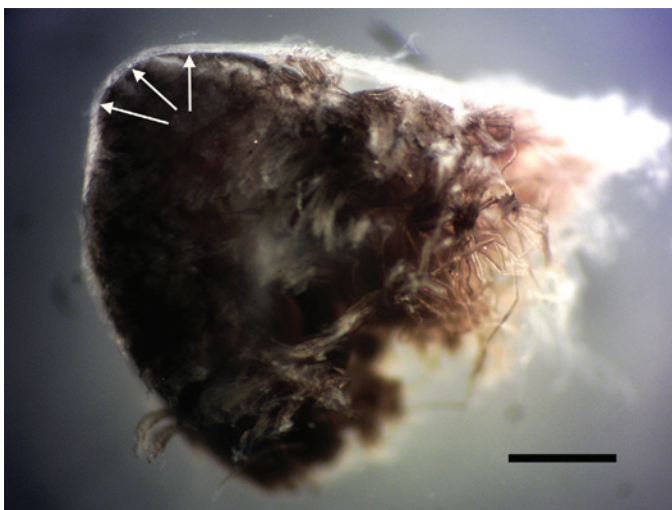


Figure 2: Cross section of avian peripheral nerve showing thin outer layer of the perineurium (arrows). Darkened nerve fibers are stained with OsO_4 . Scale bar = 0.5 mm.

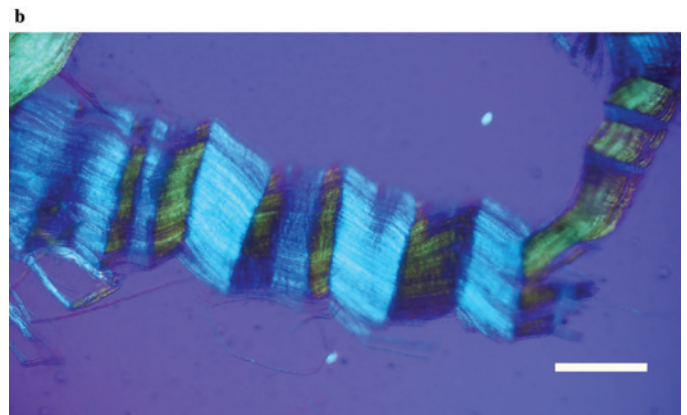
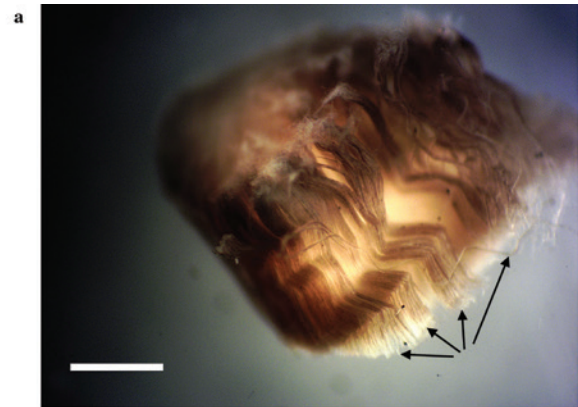


Figure 3: (a) Clumps of avian axonal fibers (arrows) darkened by OsO_4 . Scale bar = 0.125 mm. (b) Polarized light microscopy of pleated sheet of avian axonal fibers dissected from a fascicle. Scale bar = 0.125 mm.

acetone and embedded in Epon. Sections of about 20 μm were prepared with a Sorvall MT-2 ultramicrotome and affixed to glass slides for observation with polarized light.

An intact 10.5 cm diameter *Triceratops horridus* occipital condyle, HCTC-31, previously collected [37] from the Hell Creek Formation, MT (Figure 8), was pressure-fractured into

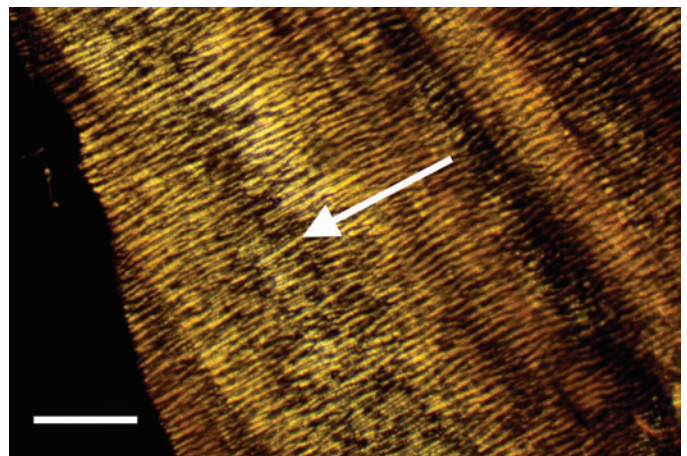


Figure 4: External view of epineurium covering avian fiber in reflected light. Note thick lightly colored collagen fibers (arrow) circumscribing the nerve. Scale bar = 0.75 mm.

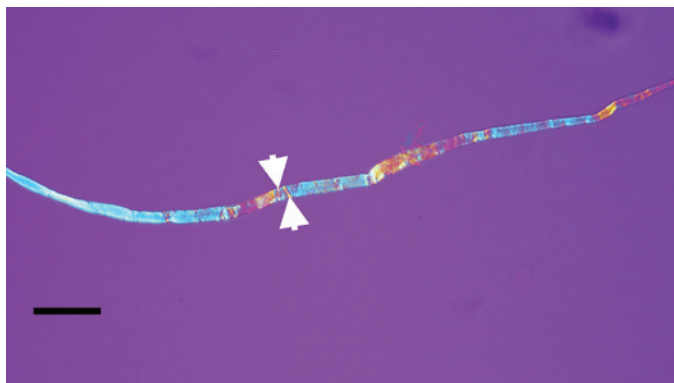


Figure 5: Avian bone nerve fascicle showing distinctive cross bars known as Bands of Fontana (arrows). Scale bar = 30 μm .




Figure 7: Avian peripheral nerve, thin sectioned to expose the clear double helical wrapping. Scale bar = 60 μm .

fragments of roughly 2 cm on a side, fixed, and decalcified as above. Whole nerve fragments and fascicles were identified and collected by fine needle forceps from the decalcification solutions.

Results

Exposed avian nerves display a thickly robust outer epineurium (Figure 1) and a thinner, compact layer of perineurium (Figure 2), which together circumscribe the bundles of fascicles within them. Clumps of individual nerve fibers, with their characteristic sinusoidal pleating, can be seen in a gross segment of the nerve (perineurium removed) after staining in OsO_4 (Figure 3a). A band of exposed avian fibers (polarized light with $\frac{1}{4}$ wave plate) is seen in Figure 3b. The outermost surface of epineurium (Figure 4), shown in reflected light, reveals bands of collagen circumscribing the layer at right angles to the long axis. Thin-sectioned whole avian nerves (Figure 7) reveal the diagnostic crosshatch-wrapping pattern described above and matches Glee's findings [7] (Figure 6). Whole decalcified avian nerves averaged 22 μm in width and 340 μm in length. An individual avian fascicle is seen in Figure 5.

A *Triceratops* condyle bone collected from the Hell Creek Formation is shown in Figure 8. Nerve fragments, collected after decalcification (Figures 9–11), were approximately 29 μm wide and averaged 211 μm in length. The collagen fibers making up the wrapping were more separated and isolated from each other, possibly a result of desiccation, compaction, and concretion over time (Figure 10). Fine debris often adhered

to the outer layer of the nerves and were not removed after repeated washing. Interestingly, swirled connective tissue wrappings, which must have separated from the nerves they



Figure 8: Intact *Triceratops* occipital condyle, collected from the Hell Creek Formation, MT. Scale bar = 3 cm.

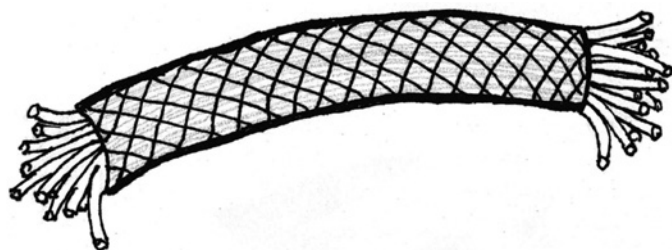


Figure 6: Peripheral nerve showing the double helix crosshatch pattern of circumferential wrapping of collagen fibers in the connective tissue sheath. After Glee, 1943 [7].

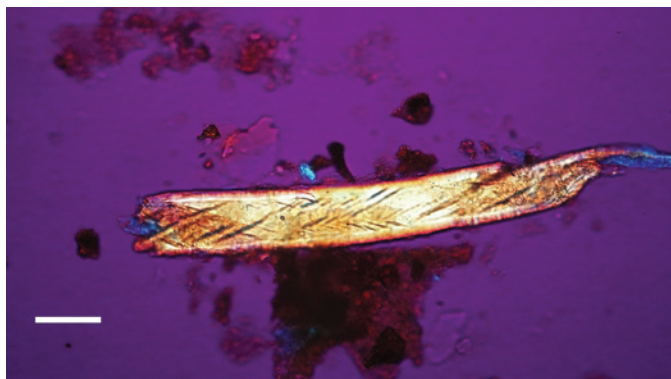


Figure 9: Bone nerve fragment harvested from *Triceratops* condyle. Note double helical wrapping of connective tissue sheath. Scale bar = 25 μm .

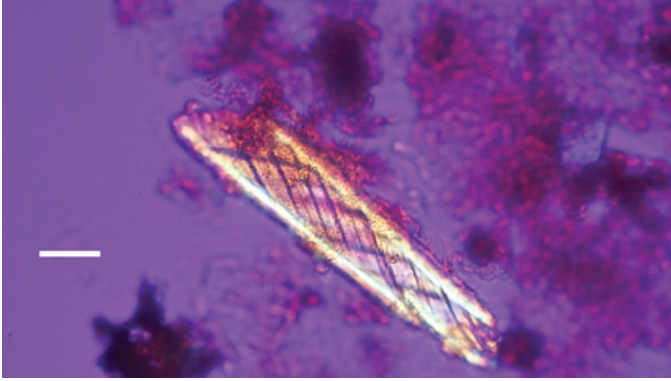


Figure 10: Bone nerve fragment harvested from *Triceratops* condyle. Note double helical wrapping of connective tissue sheath. Scale bar = 25 μ m.

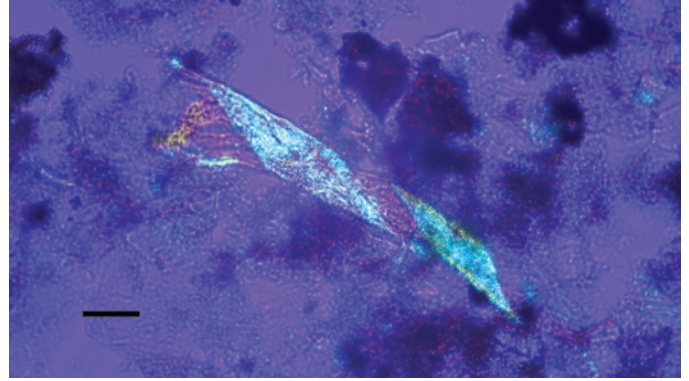


Figure 13: Bone nerve connective sheath harvested from *Triceratops* condyle. Note double helical wrapping of connective tissue sheath. Scale bar = 40 μ m.




Figure 11: Bone nerve fragment harvested from *Triceratops* condyle. Note double helical wrapping of connective tissue sheath. Scale bar = 20 μ m.

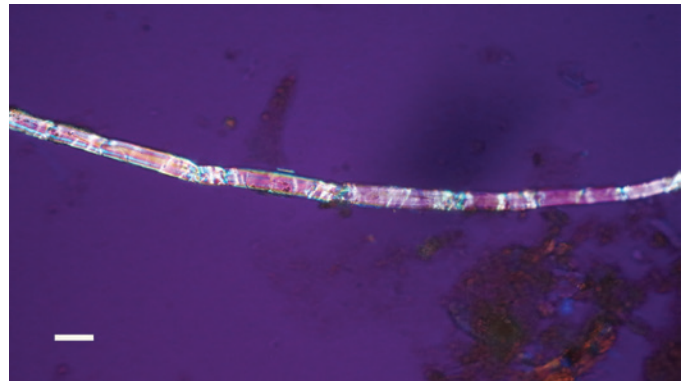


Figure 14: Bone nerve fascicle with Bands of Fontana, harvested from *Triceratops* condyle. Scale bar = 20 μ m.

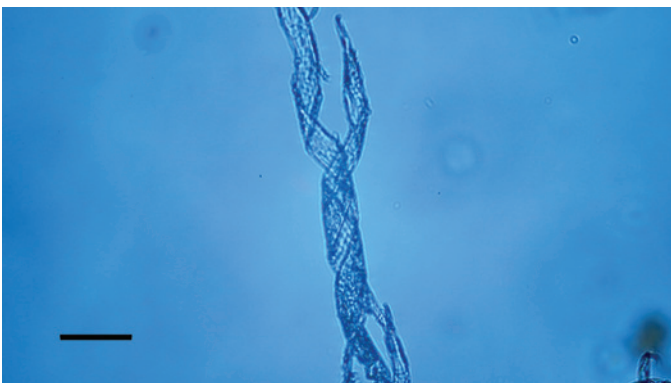


Figure 12: Bone nerve connective sheath harvested from *Triceratops* condyle. Note double helical wrapping of connective tissue sheath. Scale bar = 40 μ m.

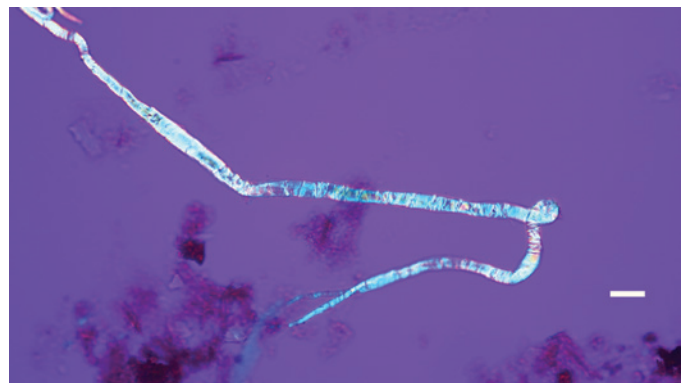


Figure 15: Bone nerve fascicle with Bands of Fontana, harvested from *Triceratops* condyle. Scale bar = 20 μ m.

once wrapped, were found in the decalcification solutions (Figures 12 and 13).

Individual dinosaur nerve fascicles (Figures 14–16), also liberated during decalcification, were flexible and tolerated repeated stretching with fine needle forceps. Serial sections made from a dinosaur nerve fragment (Figure 17a) are visualized in Figures 17b–17d. The outer connective covering (white arrows, Figures 17b and 17c) is clearly a separate layer from

the fascicle, which is blue in color and features lightly colored Bands of Fontana within it (red arrow, Figure 17c). Grooves within the outer covering (Figure 17b) extend deeply into the covering, probably due to concretion and desiccation over time.

Discussion

The diagnostic double helical wrapping of collagen in the epineurium and perineurium seen in these dinosaur nerve

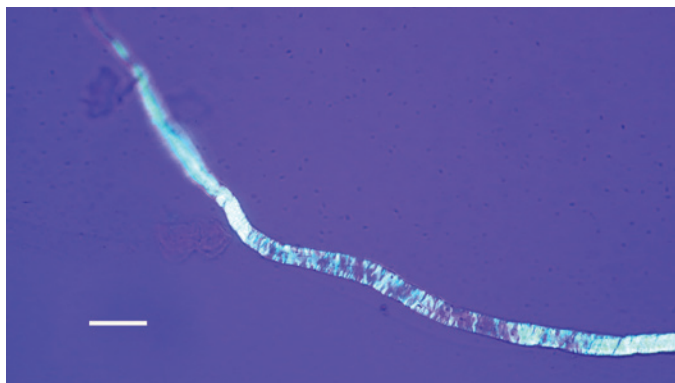


Figure 16: Bone nerve fascicle with Bands of Fontana, harvested from *Triceratops* condyle. Scale bar = 20 μ m.

fragments leads us to conclude that these are indeed nerves from bone canals of *Triceratops* occipital condyle. There is no question that more attempts must be made to secure and characterize fibers from other dinosaur taxa, and especially from

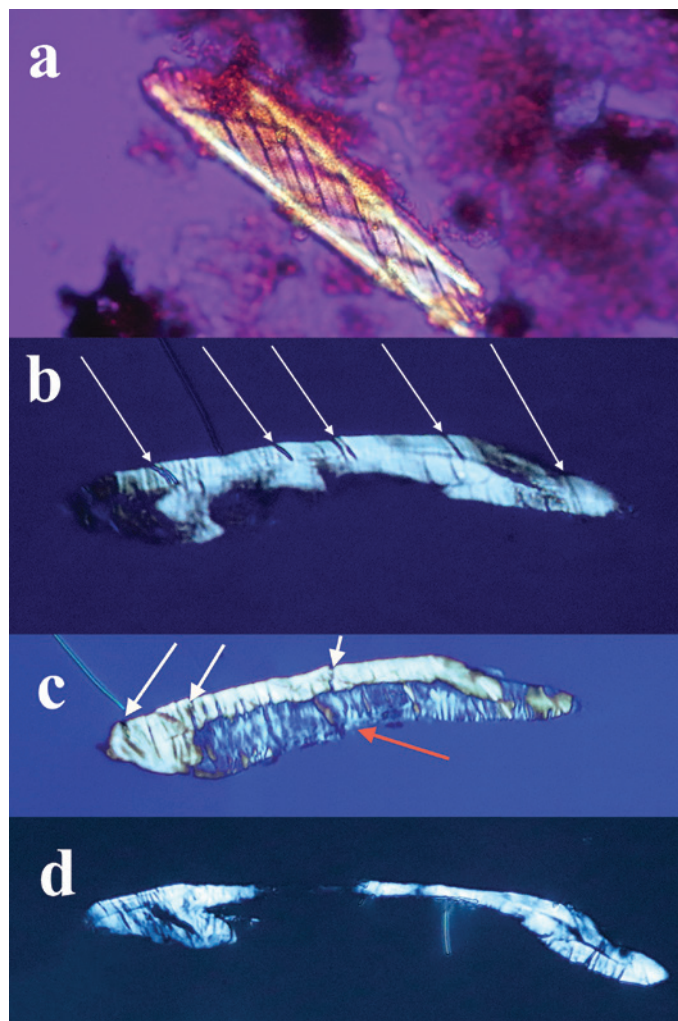


Figure 17: (a) Bone nerve fragment harvested from *Triceratops* condyle. (b–d) A series of thin sections made of the nerve. White arrows (b, c) show thick connective tissue and grooves between bands of collagen surrounding the nerve. A blue individual fascicle is seen in 17c (red arrow).

other depositional environments. These findings prompted us to re-examine hundreds of slides of decalcified material from *Triceratops* horn, rib, frill, and vertebra prepared for a previous study [37]. Birefringent nerve fragments and fibers were also observed in these preparations indicating the possible presence of nerves in all *Triceratops* specimens decalcified by us to date.

The flexibility of individual decalcified nerves was astonishing. Nerves held at each end with fine needle forceps only broke into two pieces after repeated tugging. An example of the flexibility of these nerves is seen in Figure 15 where the fascicle rotates through a gentle, unbroken loop and descends into other curvatures before terminating to a point. Remnants of Bands of Fontana (thin white lines due to the sinusoidal wave within sheets of axons) were evident in all fascicles collected (Figures 5 and 14–16).

Sections of dinosaur fascicles reveal a thick outer connective layer made up of collagen fibers that evidently pulled apart from each other (possibly an artifact of desiccation and concretion), which created thin, uniform, and parallel slits into the layer from the outer epineurium to the fascicle (white arrows, Figures 17b and 17c). The exposed fascicle within the nerve (Figure 17c) displays (mostly vertical) Bands of Fontana. Swirled connective tissue wrappings, devoid of the fascicles that they must have protected, are also probably an artifact of desiccation and separation between the connective tissue layers (Figures 12 and 13). The separated wrappings maintain the double helical pattern they exhibited in living tissue, another feature of the durability and robust construction of the connective tissue layers of dinosaur nerves.

Conclusions

A comparison of nerves isolated from decalcified bone of commercially available chicken legs and a *Triceratops* occipital condyle from the Hell Creek Formation in Montana is presented. Based on the comparison we identify soft and flexible nerve fragments from dinosaur remains for the first time. We believe that non-permineralized dinosaur bones represent an untapped treasure of soft and flexible tissue elements that simply await efforts to expose them.

References

- [1] M Malpighi, *Phil Trans Roy Soc* 2 (1666) 491–92.
- [2] A van Leeuwenhoek, *Phil Trans Roy Soc* 10 (1675) 378–80.
- [3] A van Leeuwenhoek, *Phil Trans Roy Soc* 15 (1685) 883–95.
- [4] F Fontana, *Traité sur le venin de la vipère sur les poisons américains sur le laurier-cerise* (1781) Nyon l'aîné, Paris.
- [5] A Key and G Retzius, *Archiv fur Mikrosk Anat* 9 (1873) 308–86.
- [6] ML Ranvier, *Leçons sur l'histologie du système nerveux* (1878) Savy, Paris.
- [7] P Glees, *J Anat* 77 (1943) 153–59.
- [8] PK Thomas, *J Anat* 97 (1963) 35–44.
- [9] HJ Gamble, *J Anat* 98 (1964) 17–25.
- [10] HJ Gamble and RA Eames, *J Anat* 98 (1964) 655–63.
- [11] S Sunderland, *Brain* 88 (1965) 841–54.
- [12] FN Low, in *The Peripheral Nerve*, ed. DN Landon, Chapman and Hall, London, 1976, 159–87.
- [13] T Ushiki and C Ide, *Cell Tissue Res* 260 (1990) 175–84.
- [14] C Stolinski, *J Anat* 185 (1994) 211–12.
- [15] C Stolinski, *J Anat* 186 (1995) 123–30.

- [16] KS Topp and BS Boyd, *Phys Ther* 86(1) (2006) 92–109.
- [17] KS Topp and BS Boyd, *J Hand Ther* 25(2) (2012) 142–52.
- [18] ME Jabaley et al., *J Hand Surg* 5A (1980) 1–18.
- [19] A Chvátal, *J Hist Neurosci* 24(3) (2015) 268–91.
- [20] LM Alvey et al., *J Anat* 234 (2019) 165–78.
- [21] HE Setterfield and HM Weaver, *Ohio J Sci* 37 (1937) 65–74.
- [22] CM Serre et al., *Bone* 25 (1999) 623–29.
- [23] C Chenu, *J Musculoskel Neuron Interact* 4 (2004) 132–34.
- [24] B Burt-Pichat et al., *Endocrinology* 146 (2005) 503–10.
- [25] R Jacobs et al., *Oral and Maxillofacial Radiol* 103 (2007) 683–93.
- [26] RE Tomlinson et al., *Frontiers Endocrinol* 11 (2020) 1–12.
- [27] PW Mantyh, *Eur J Neurosci* 39 (2014) 508–19.
- [28] EA Buchholtz and EA Seyfarth, *BioScience* 51 (2001) 674–82.
- [29] S Chatterjee and Z Zheng, in *Thunder Lizards: The sauropodomorph dinosaurs*, eds. V Tidwell and K Carpenter, Indiana Univ Press, Bloomington, 2005, 199–211.
- [30] AM Balanoff et al., *Am Museum Novitates* 3677 (2010) 1–32.
- [31] A Paulina-Carabajal, *Anat Rec* 295 (2012) 2141–56.
- [32] SV Saveliev et al., *Paleontol J* 46 (2012) 79–91.
- [33] F Knoll et al., *PLOS ONE* 7 (2012) e30060: 1–16.
- [34] P Cruzado-Caballero et al., *PeerJ* 802 (2015) e802: 1–16.
- [35] A Paulina-Carabajal et al., *Palaeogeog Palaeoclimatol Palaeoecol* 494 (2018) 135–46.
- [36] R Sakagami and S Kawabe, *PeerJ* (2020) e9888. doi.org/10.7717/peerj.9888
- [37] MH Armitage and KL Anderson, *Acta Histochem* 115 (2013) 603–08.

MT

QUARTER-PAGE
ADVERTISEMENT
89 mm x 114 mm

HALF-PAGE
ADVERTISEMENT
89 mm x 237 mm